

An *In Vivo* Implantation Study in New Zealand White Rabbits for Granular Hydroxyapatite

Hafiz A.¹, KA Khalid¹, Yusof A.¹, Azril MA.¹, Shukrimi A.¹, Nazri MY.¹, Aminudin CA.¹, Zamzuri Z.¹, Fazan F.²
¹Department of Orthopaedics, Traumatology & Rehabilitation, International Islamic University Malaysia, ²Advance Materials Research Centre, Kedah, Malaysia

Introduction: We developed hydroxyapatite (HA) granules made from local raw materials (GranuMaS™), which have been fabricated using a novel method (Patent (Pending) No. PI 2004 0748). GranuMaS™ have been fully characterized using X-ray diffraction, scanning electron microscopy, energy dispersive x-ray, Fourier transform infra-red spectroscopy and inductively coupled plasma methods. It has also been shown to comply with the ASTM F1185 - 88 (1993) specification standards.

Biocompatibility studies have been performed on the product, which include neutral red cytotoxicity assay using cultured fibroblast and CRL-1427 osteoblast cells; MTT (Tetrazolium Salt) assay; cytotoxicity studies for apoptosis using Acridine Orange / Propidium Iodide (AO/PI) dual staining of V79 cells in DMEM; and COMET assay genotoxicity studies using L-929 (normal mouse epithelial) cells.

An *in vivo* implantation study involving New Zealand White rabbits were carried out in the course of this study.

Materials and Methods: HA granules of between 250 to 500 µm in diameter were implanted into a 9mm by 4.5mm defect made in the proximal metaphyseal region of the rabbits' left tibia. The tibia was harvested at 2, 3, 4, 6 and 12 weeks. The retrieved specimens were processed to produce undecalcified tissue sections using a hard tissue band cutting and microgrinding system (EXAKT Apparatebau, Germany). Prepared slides were analyzed under the light microscope using compound polarized light, Toulidine Blue, Masson Goldner's Trichrome and von Kossa stains.

Results and Discussion: New bone formation is seen even at 2 weeks post-implantation, which further consolidates at 3, 4 and 6 weeks. At 12 weeks the new bone between the granules are well-formed and the cortical defects made have closed off with well-formed lamellar bone seen between the granules. There is direct apposition of the new bone to the granules. The new bone seen with bridging of the medullary cavity and no major voids or defects found. No evidence of any fibrous or inflammatory tissue was seen.

Conclusions: GranuMaS™ is osteoconductive and biocompatible when implanted in rabbits. It could be used as an alternative bone graft substitute, as there is profound new bone formation in-between and around the granules.

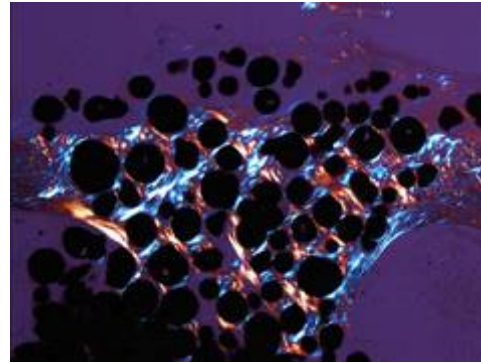


Figure 1: 12 weeks post implantation seen under compound polarized light (magnification 2.5x)

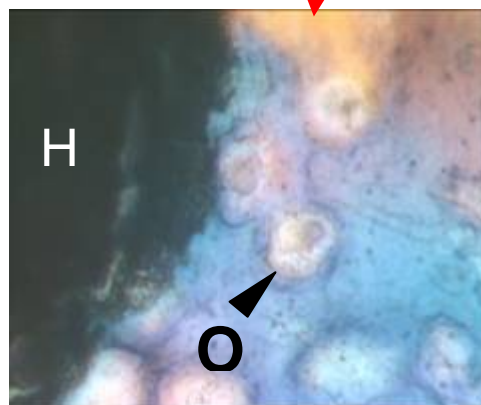
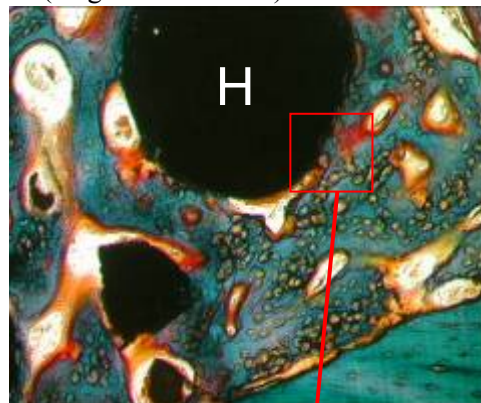

Figure 2: Masson Goldner's Trichrome at 3 weeks of implantation. (HA – hydroxyapatite, O – osteocytes at 10X and 100X magnification)